

MYOPATHY ADVERSE DRUG REACTION ASSOCIATED WITH LANSOPRAZOLE: A CASE REPORT

Lidya Karina¹, Hanny Cahyadi^{1,2}

¹ Faculty of Pharmacy, University of Surabaya, Surabaya

² National Hospital, Boulevard Famili Sel. No.Kav. 1, Surabaya

Correspondence: Lidya Karina

Email: lidyakarina@staff.ubaya.ac.id

ABSTRACT: Proton pump inhibitor has been reported to cause myopathic adverse drug reactions in several overseas countries. Unfortunately, this case has never been raised and has not received much attention in Indonesia. A case about myopathy associated with lansoprazole in 48-years old man has been recently reported in Indonesia. Assessment methods used were time series data collection followed by causality analysis using Naranjo Scale. The results of analysis revealed a Naranjo Scale of 9, which was interpreted as definite. This report concluded that lansoprazole could triggered myopathy adverse drug reaction in some sensitive patient. The mechanism presumably through inhibition of H^+K^+ -ATPase in other tissue which can lead destruction of myofibril and leakage of calcium, pottasium, phosphate, myoglobin, creatine phosphokinase, lactate dehydrogenase, and aspartate transaminases from the muscle. This case report aims to remind health professionals to pay more attention at possible myopathy adverse drug reactions in the use of lansoprazole and other proton pump inhibitors, so that more serious adverse drug reactions could be prevented.

Keywords: Proton pump inhibitor; Lansoprazole; Myopathy

1. Introduction

Proton pump inhibitors (PPI) are the first line recommendation to relieve severe gastrointestinal problem caused by over-secretion of gastric acid. PPI are a class of medication which inhibit the H⁺K⁺-ATPase in parietal cells to suppress gastric acid secretion [1,2]. As of 2015, there are five PPI that are approved both by United States and Indonesian Food and Drug Administration (FDA) including omeprazole, lansoprazole, esomeprazole, rabeprazole, and pantoprazole [3,4].

PPI become the first line recommendation of acid-related disorder because it is considered as effective and safe [2,4,5]. Since its FDA approval, several case report from overseas countries that reported myopathy adverse drug reaction in patients who received PPI have been slowly emerging [5,8]. Myopathy is a term used to define any disease of the muscle that presented as muscle cramps, myalgia, joint pain, leg pain, back pain, or muscle weakness [1,5].

An evaluation of myopathy conducted by Capogrosso-Sansone *et al.* (2014) using the data obtained from 255,548 patients who received PPI since January 1988 until July 2014 reported adjusted odd ratio (aOR) (95% CI) of 1.237 (1.101-1.389), $p < 0.001$ [9]. Lansoprazole as one type of the PPI was reported to have higher myopathy and rhabdomyolysis aOR compared to

omeprazole. Lansoprazole demonstrated aOR (CI 95%) of 2.687, 95%CI:1.778-4.062, $p < 0.001$ while omeprazole demonstrated aOR (CI 95%) of (aOR:1.996, 95%CI:2.027-4.428, $p < 0.001$) [9]. SIDER data base of lansoprazole (<http://sideeffects.embl.de/drugs/3883/>) demonstrated that myopathy or myositis side effect has been reported on post marketing surveillance, but there has been no report on the frequency of the incidence. (10,11)

Neither PPI induced myopathy nor lansoprazole induced myopathy case has been reported in Indonesia. In this article, we review a case report of myopathy adverse drug reaction associated with lansoprazole in an Indonesian patient. This case report aims to remind health professionals in Indonesia to pay more attention at possible myopathy adverse drug reactions in the use of lansoprazole and other proton pump inhibitors. Therefore, more serious adverse drug reactions could be prevented.

2. Case Presentation

Mr. LD a 48-year-old male patient, 70 kg, 165 cm, was complaining heartburn, epigastric pain, and dyspepsia on June 20th, 2017. He was visiting his doctor in outpatient clinic at a private hospital in Surabaya and was diagnosed as gastritis. He

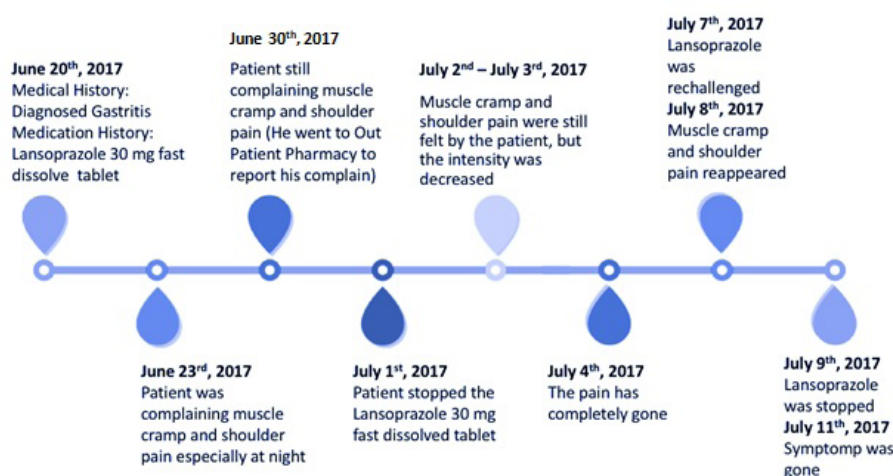


Figure 1. Myopathy time series of the patient. Myopathy was developed three days after starting lansoprazole for the first time and later on when it is restarted. Myopathy was recovered after lansoprazole was discontinued on both occasion.

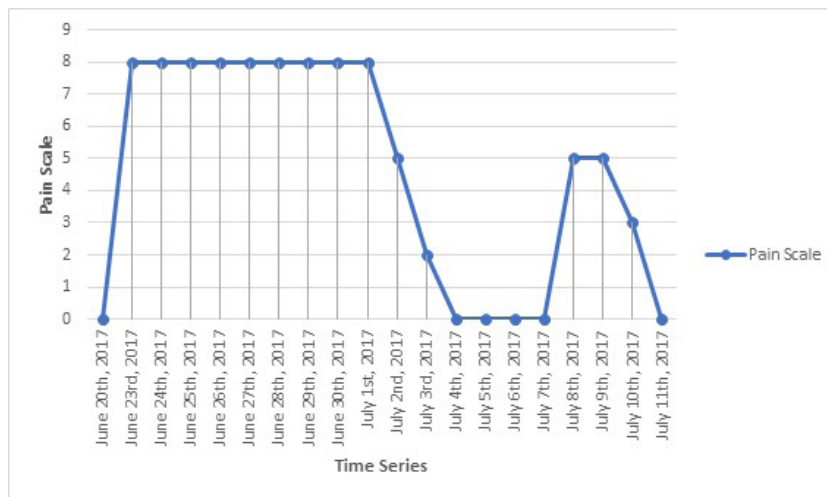


Figure 2. Time series of patient myopathy pain scale

was prescribed 30 mg fast dissolved lansoprazole once daily. Patient has neither medical history nor medication history. On June 23rd, 2017 patient started complaining muscle cramp and shoulder pain (myopathy) especially at night. On June 30th, 2017 patient was still complaining the same condition and went back to the outpatient pharmacy to report his condition (pain scale: 8 out of 10). The outpatient pharmacist asked for other possible condition such as injury or statin consumption history but found nothing has been the particular cause of the complains. The pharmacist has consulted the doctor and suggested the patient to stop the lansoprazole. On July 1st 2017 the patient stopped taking lansoprazole. On July 2nd – July 3rd, 2017, after the medication was stopped the patient still felt the pain but the intensity decreases (pain scale: 3 out of 10). On July 4th, 2017 the muscle cramp and shoulder pain (myopathy) were completely gone. Pharmacist asked patient to retake the medication and it resulted with the same complain (pain scale: 7 out of 10). The pain was relieved when the medication has been stopped for two days (pain scale: 0 out of 10).

3. Results and discussion

Myopathy is defined as the acute or subacute

manifestation of muscle weakness, myalgia, and sometimes presented in the laboratory data as elevated creatine phosphokinase level or myoglobinuria. There are several causes of myopathy such as family history of periodic paralysis or muscle dystrophy, personal medical history of autoimmune disease, endocrinopathy, renal insufficiency, alcoholism, previous episodes of sever weakness, muscle injury, occupational or travel history that caused potential ingestion of barium chloride or carbonate, and medication history such as lipid lowering agents, antiretroviral, and colchicine [12,13]. The patient had none of this condition, except a history of gastritis and lansoprazole.

Lansoprazole is included in PPI class therapy. PPI are an important class of medication for the management of over secretion of gastric acid, GERD, Barret's esophagus, peptic ulcer and gastrointestinal bleeding [14]. Generally, PPI are very safe medication, but a few case reports have implicated that their used may associated with myopathy adverse drug reaction [1,5]. A review of 12 case reports conducted by Colmenares *et al.* (2017) has demonstrated that patients developing myopathy after PPI administration. One of the reported case was also happened after the administration of lansoprazole.

In this 48-year-old patient case, a Naranjo Scale analysis was performed. The results of ana-

Table 1. Naranjo Scale

No	Question	Yes	No	Do Not Know	Score
1	Are there previous conclusive report on this reaction	+1	0	0	1
2	Did the adverse event appear after the suspected drug was administered?	+2	-1	0	2
3	Did the adverse event improve when the drug was discontinued or a specific antagonist was administered?	+1	0	0	1
4	Did the adverse event reappear when the drug was readministered?	+2	-1	0	2
5	Are there alternative causes that could on their own have caused the reaction?	-1	+2	0	2
6	Did the reaction reappear when a placebo was given?	-1	+1	0	0
7	Was the drug detected in blood or other fluids in concentrations known to be toxic?	+1	0	0	0
8	Was the reaction more severe when the dose was increased or less severe when the dose was decreased?	+1	0	0	0
9	Did the patient have a similar reaction to the same or similar drugs in any previous exposure?	+1	0	0	0
10	Was the adverse event confirmed by any objective evidence?	+1	0	0	1
Total Naranjo Score					9

Table 2. Naranjo Algorithm - ADR Probability Scale Naranjo

Score	Question
Total Score ≥ 9	Definite. The reaction (1) followed a reasonable temporal sequence after a drug or in which a toxic drug level had been established in body fluids or tissues, (2) followed a recognized response to the suspected drug, and (3) was confirmed by improvement on withdrawing the drug and reappeared on re-exposure.
Total Score 5 to 8	Probable. The reaction (1) followed a reasonable temporal sequence after a drug, (2) followed a recognized response to the suspected drug, (3) was confirmed by withdrawal but not by exposure to the drug, and (4) could not be reasonably explained by the known characteristics of the patient's clinical state.
Total Score 1 to 4	Possible. The reaction (1) followed a temporal sequence after a drug, (2) possibly followed a recognized pattern to the suspected drug, and (3) could be explained by characteristics of the patient's disease.
Total Score ≤ 0	Doubtful. The reaction was likely related to factors other than a drug.

lysis revealed a Naranjo Scale of 9, which was interpreted as definite. It is shown a high certainty, that lansoprazole is suspected as a trigger of myopathy. The following are the results of the Naranjo scale analysis (Table 1 and Table 2).

The potential mechanism of myopathy associated with lansoprazole has not yet been elucidated. Lansoprazole is known to bind specifically to H⁺K⁺-ATPase at the parietal cell on the stomach. H⁺K⁺-ATPase is present not only in parietal cells but also in other tissue including the muscle cells. Blocking H⁺K⁺-ATPase may induce destruction of myofibril and leakage of calcium, potassium, phosphate, myoglobin, creatine phosphokinase, lactate dehydrogenase, and aspartate transaminases from the muscle.

Myopathy time to onset was occurred with the first week of PPI in 9 cases reported by Clark and Strandel (2006) and in 2 cases reported by Duncan and Howards (2017). The reaction occurred between 14 days to 4 months of PPI treatment in 3 cases was reported by Clark and Strandel while 3 cases was reported on Duncan and Howden (2017) [1,15]. Where in Mr. LD cases the first three days after Lansoprazole was first administered.

Interestingly Clark and Strandel (2006) the myopathy syndroms even more severe in 57% of cases where concomitant medication was used. The co-reported medications were statin taken concomitantly (34 case reports), clarithromycin (11 case reports), aspirin (15 case reports), and ranitidine (13 case reports). Which none of the medication was noted in Mr. LD case.

In total of 292 cases reported by Clark and Strandel (2006) the analysis result demonstrated that 69 patients recovered when the drug was stopped and in 15 patients, the reaction re-occurred when the drug was re-challenged [1]. This profile was similar compared to the profile of Mr. LD in this article. Mr. LD myopathy symptoms was fully terminated when lansoprazole was stopped for three days, and the symptoms of

myopathy was positive when lansoprazole was re-challenged.

The profile single administered lansoprazole induced myopathy in Mr. LD case was also similar with several cases reported both in Clark and Strandel (2006) and Duncan and Howden (2017). In 33% of the 292 cases reported by Clark and Strandel (2006) the PPI was a single administered drug. In 3 cases reported by Duncan and Howden (2017) the PPI was also a single administered drug [1,15].

Myopathy associated with lansoprazole did not typically result in long-term effects. The symptoms were gone less than a week post-discontinuation of lansoprazole. Although the prevalence is rare, physician, pharmacist and other health care professional should put their consideration on it. Lack of consideration and late detection of the symptoms might lead to more severe side effect such as rhabdomyolysis as reported on Duncan and Howden (2017) and Tanaka *et al.* (2014) [15,16].

4. Conclusions

A causal association of myopathy with lansoprazole is consistent with literature review. This case report supported a causal association with Naranjo Scale of 9, which is described as definite. Myopathy associated with lansoprazole did not typically result in long-term effects after the medication was stopped. Although myopathy is a rare adverse drug reaction in lansoprazole or other PPI, it can be a serious side effect that should be considered when dispense acid suppression medication to patients.

Acknowledgement

Author would like to acknowledge Mr. LD for giving the chance to take him as a subject in this case report. University of Surabaya and National Hospital Surabaya who supported the decision to submit the manuscript for publication.

Daftar pustaka

- Clark DWJ, Strandell J. Myopathy including polymyositis: a likely class adverse effect of proton pump inhibitors? *Eur J Clin Pharmacol*. 2006;62(6):473-9.
- Moayyedi PM, Lacy BE, Andrews CN, Enns RA, Howden CW, Vakil N. ACG and CAG Clinical Guideline: Management of Dyspepsia. *Am J Gastroenterol*. 2017;112(7):988-1013.
- 1.3.4 Penghambat Pompa Proton | PIO Nas [Internet]. [cited 2018 Aug 4]. Available from: <http://pionas.pom.go.id/ioni/bab-1-sistem-saluran-cerna-0/13-antitukak/134-penghambat-pompa-proton>
- 25 Years of Proton Pump Inhibitors: A Comprehensive Review [Internet]. [cited 2018 Aug 4]. Available from: <https://www.ncbi.nlm.nih.gov/pmc/articles/PMC5221858/#!po=2.17391>
- Colmenares and Pappas - 2017 - Proton Pump Inhibitors Risk for Myopathy.pdf [Internet]. [cited 2018 Aug 4]. Available from: <http://journals.sagepub.com/doi/pdf/10.1177/1060028016665641>
- Vaezi MF, Yang Y-X, Howden CW. Complications of Proton Pump Inhibitor Therapy. *Gastroenterology*. 2017;153(1):35-48.
- Nozaki M, Suzuki T, Hirano M. Rhabdomyolysis associated with omeprazole. *J Gastroenterol*. 2004;39(1):86-86.
- Faucheux JM, Tournebise P, Viguier A, Arne-Bes MC, Larrue V, Géraud G. Neuromyopathy secondary to Omeprazole treatment. *Muscle Nerve*. 1998;21(2):261-2.
- Capogrosso-Sansone A, Galiulo MT, Tuccori M, Mantarro S, Montagnani S, Convertino I, et al. Evaluation of reporting risk for myopathy using the Italian Adverse Drug Reaction Spontaneous Reporting Database: proton pump inhibitors and their interaction with statins. 2014;1.
- Side effect information for Lansoprazole [Internet]. [cited 2018 Aug 14]. Available from: <http://sideeffects.embl.de/drugs/3883/>
- Uncover the Underlying Mechanism of Drug-Induced Myopathy by Using Systems Biology Approaches [Internet]. [cited 2018 Aug 15]. Available from: <https://www.hindawi.com/journals/ijg/2017/9264034/>
- Valiyil R, Christopher-Stine L. Drug-related Myopathies of Which the Clinician Should Be Aware. *Curr Rheumatol Rep*. 2010;12(3):213-20.
- Myopathies: Practice Essentials, Background, Pathophysiology. 2018 Jul 5 [cited 2018 Aug 5]; Available from: <https://emedicine.medscape.com/article/759487-overview#a1>
- Mukherjee S, Jana T, Pan J-J. Adverse Effects of Proton Pump Inhibitors on Platelet Count: A Case Report and Review of the Literature. *Case Rep Gastrointest Med*. 2018;1-5.
- Duncan SJ, Howden CW. Proton Pump Inhibitors and Risk of Rhabdomyolysis. *Drug Saf*. 2017;40(1):61-4.
- Tanaka K, Nakada T-A, Abe R, Itoga S, Nomura F, Oda S. Omeprazole-associated rhabdomyolysis. *Crit Care* [Internet]. 2014 [cited 2018 Aug 6];18(4). Available from: <https://www.ncbi.nlm.nih.gov/pmc/articles/PMC4243722/>